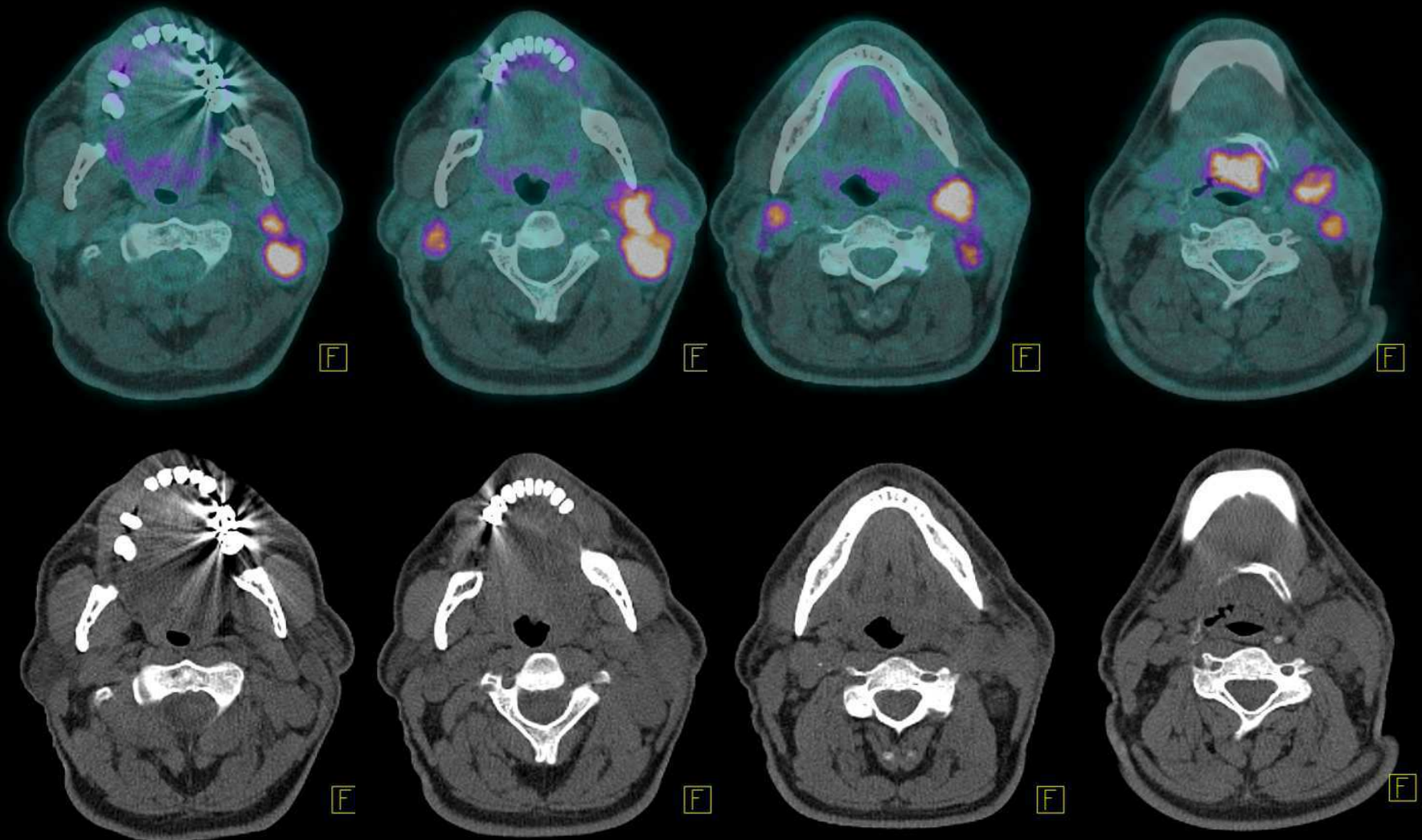


Tumeurs de la sphère ORL

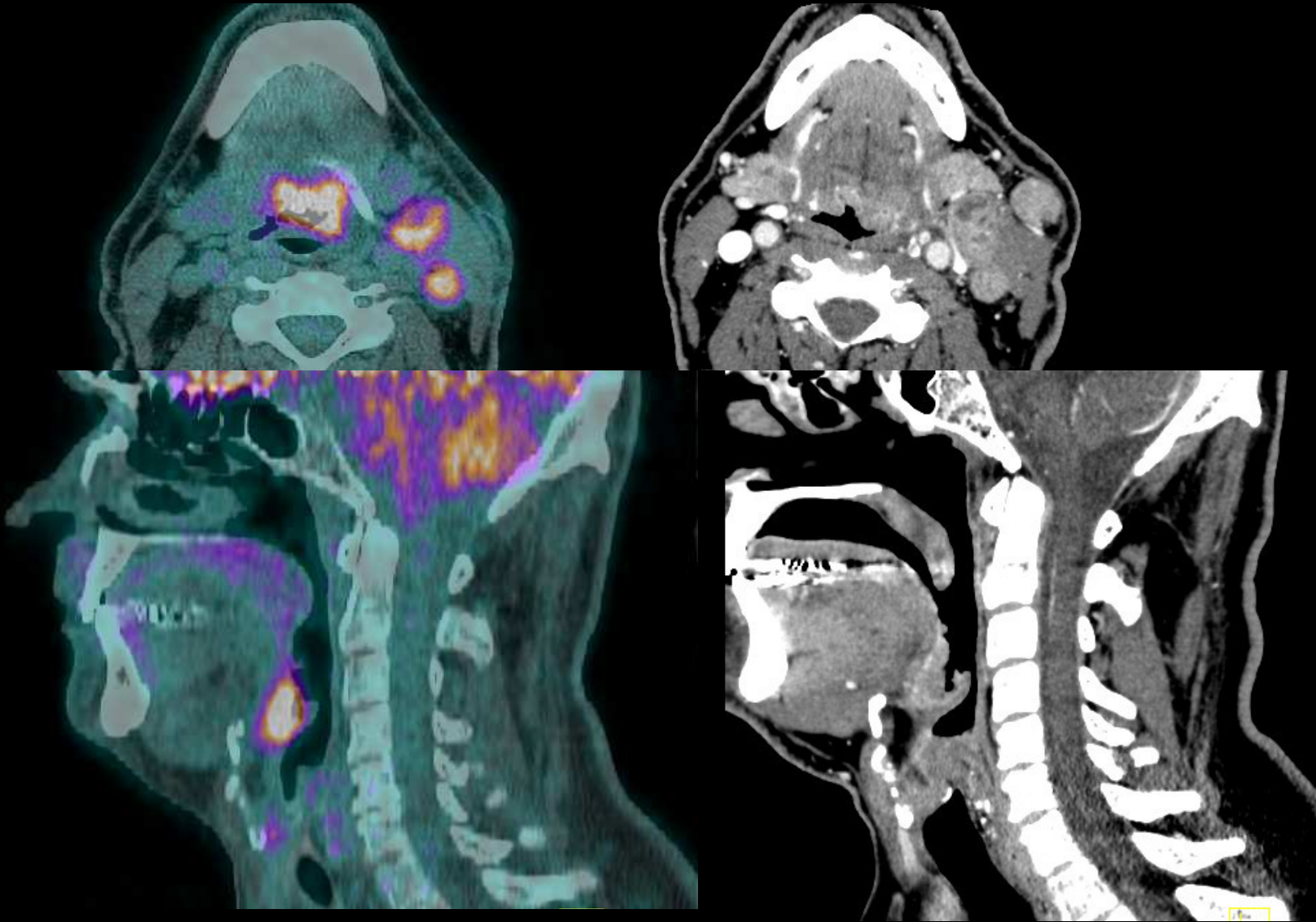
TEP ^{18}F FDG, cas cliniques

N. Didot - Médecine Nucléaire

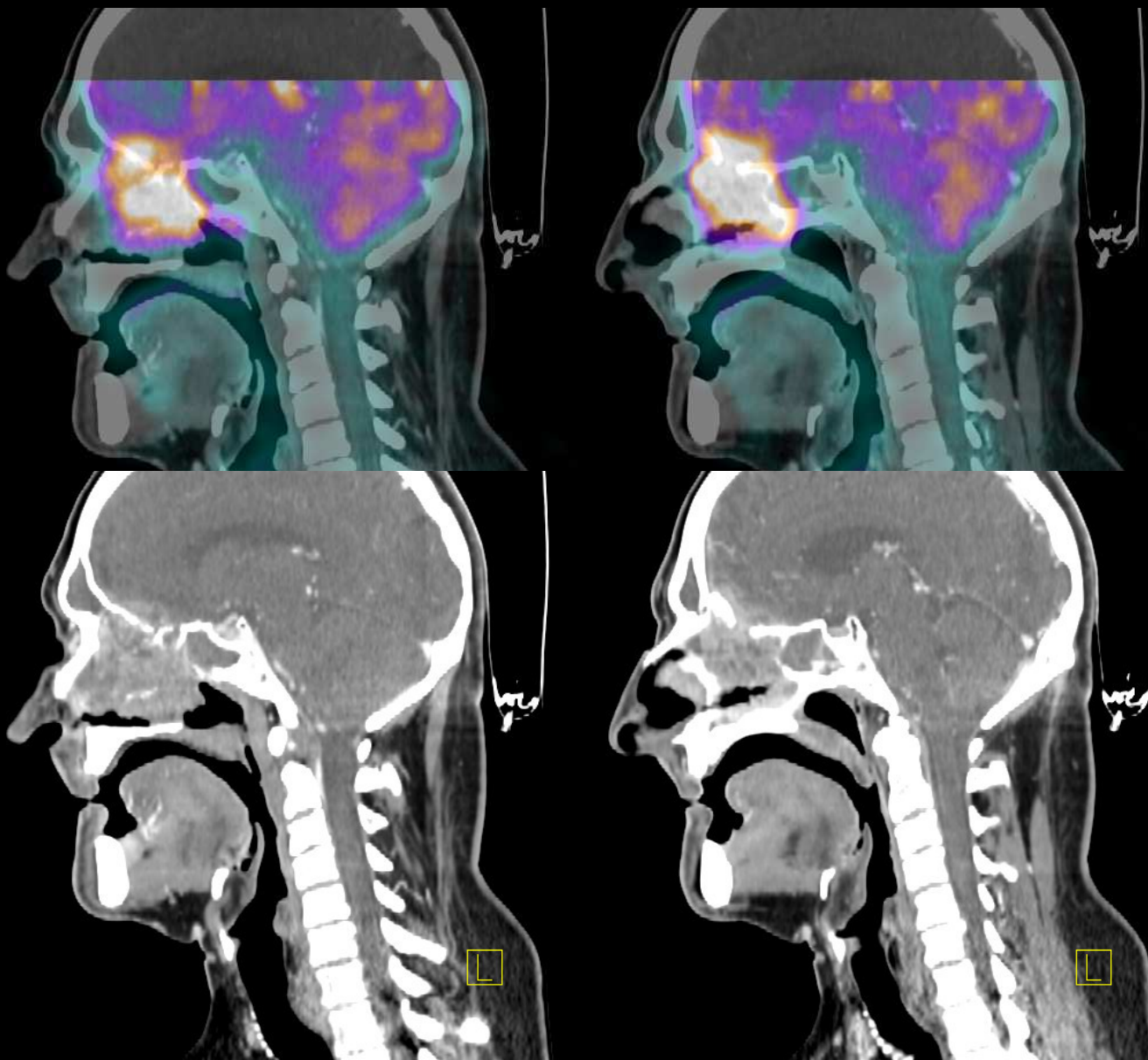
Patient 1 – Masse ganglionnaire latéro cervicale sans primitif identifié



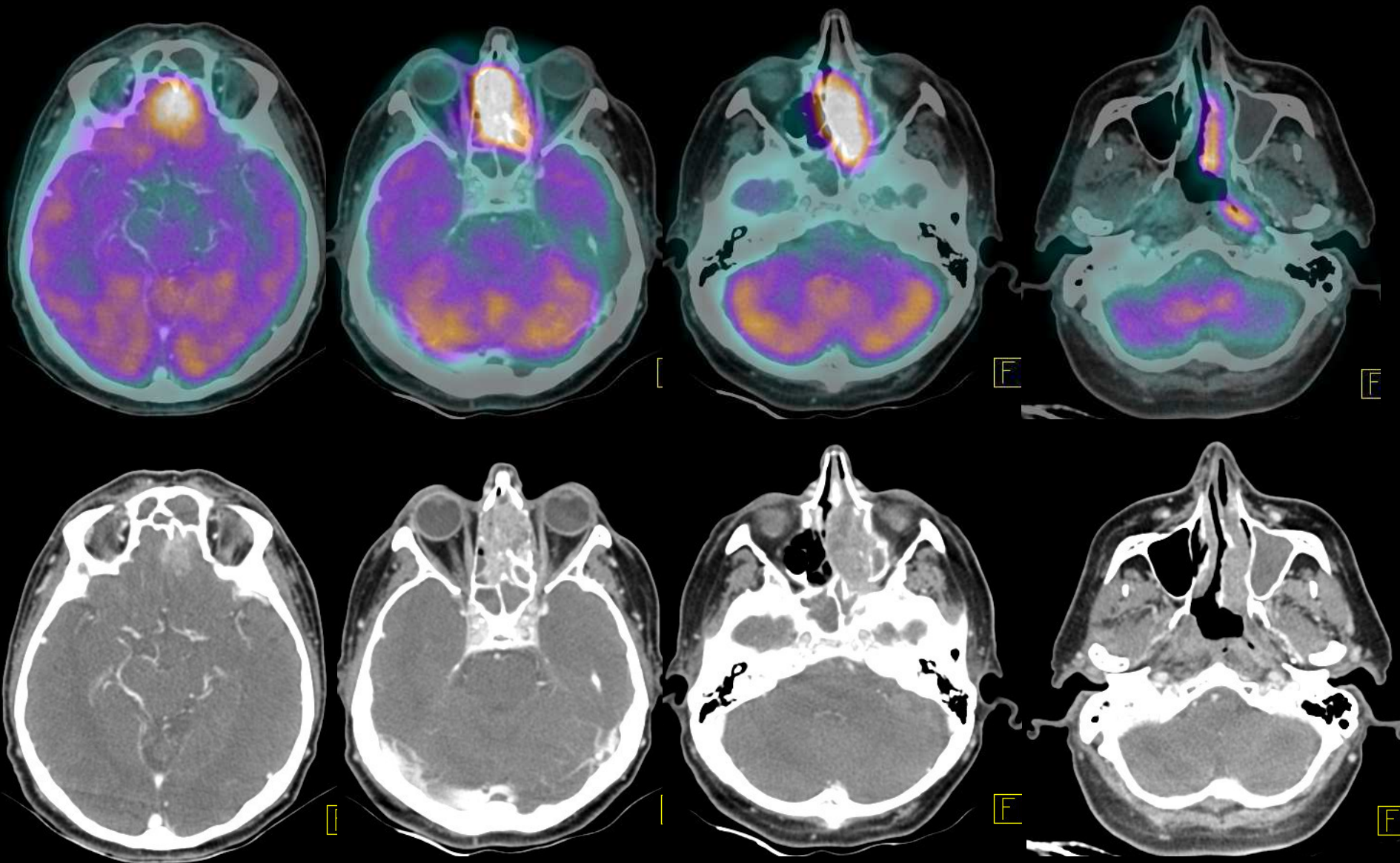
Patient 1 – Masse ganglionnaire latéro cervicale sans primitif identifié



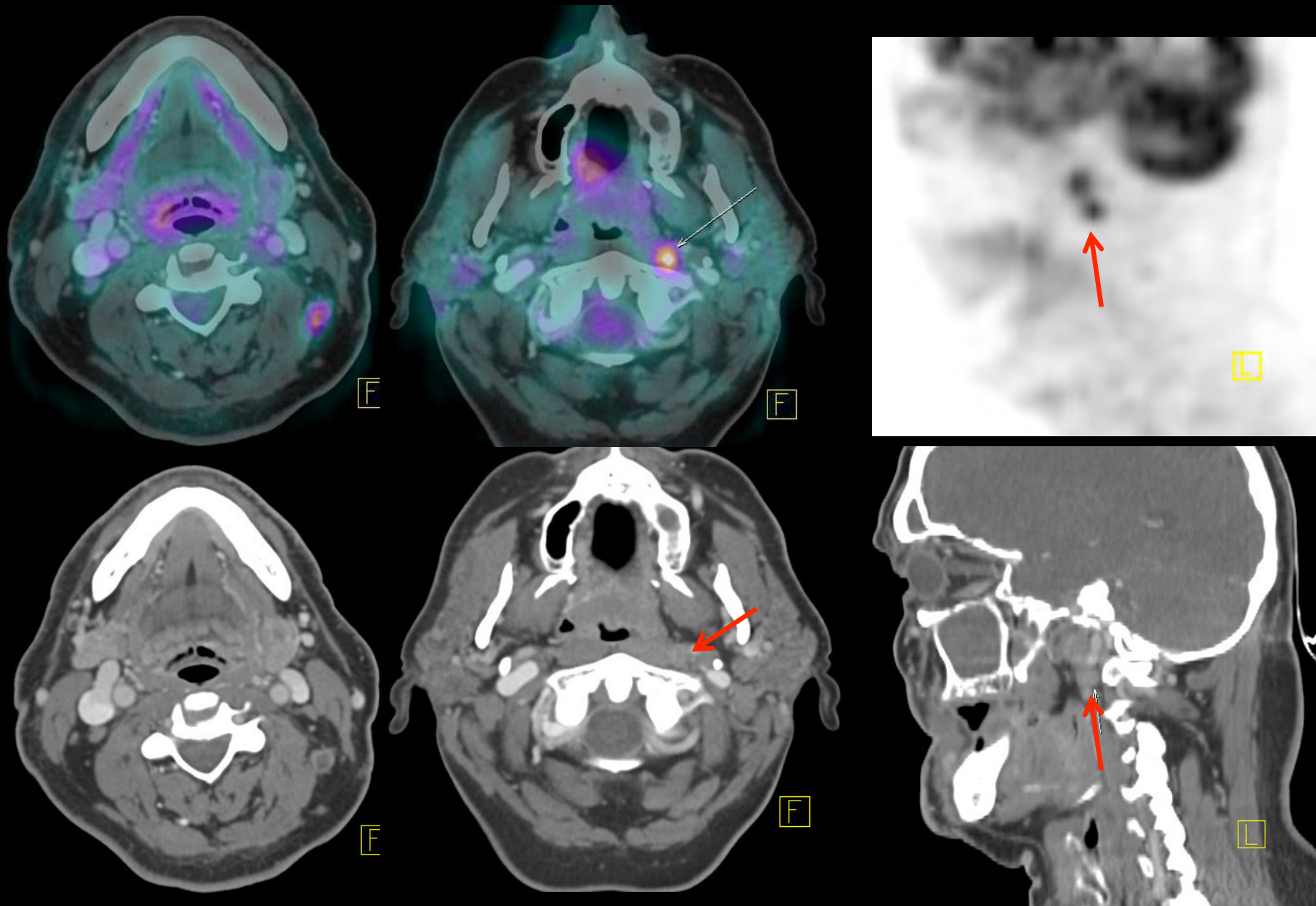
Patient 2 – Bilan d'extension d'une tumeur ethmoïdale



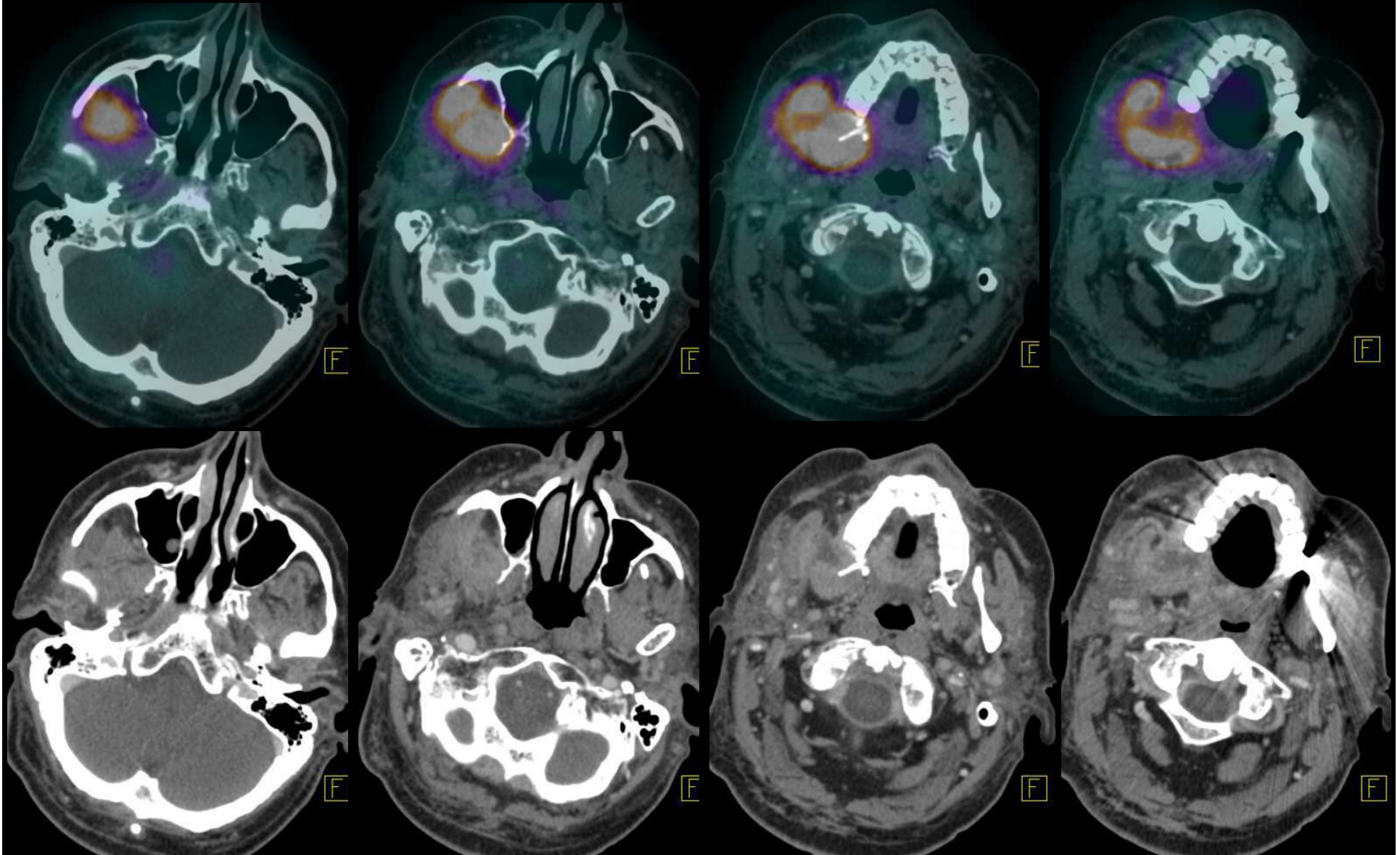
Patient 2 – Bilan d'extension d'une tumeur ethmoïdale



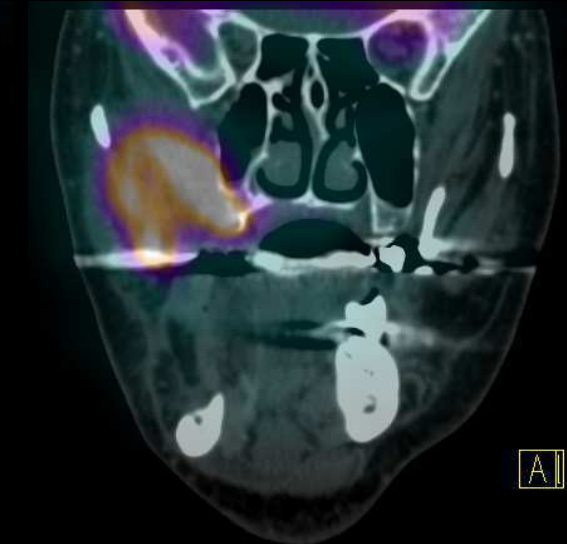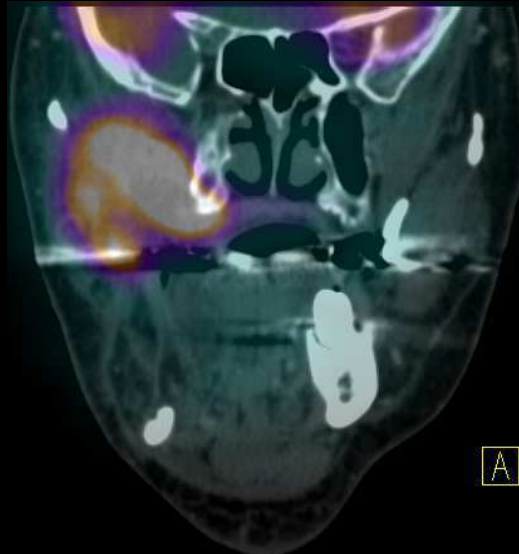
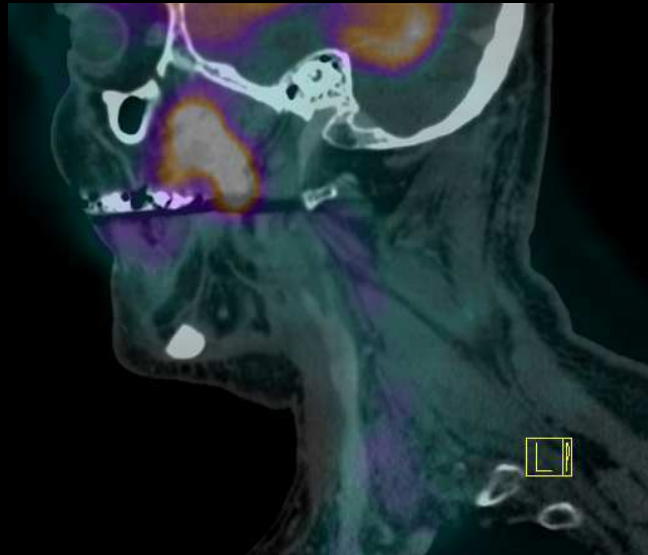
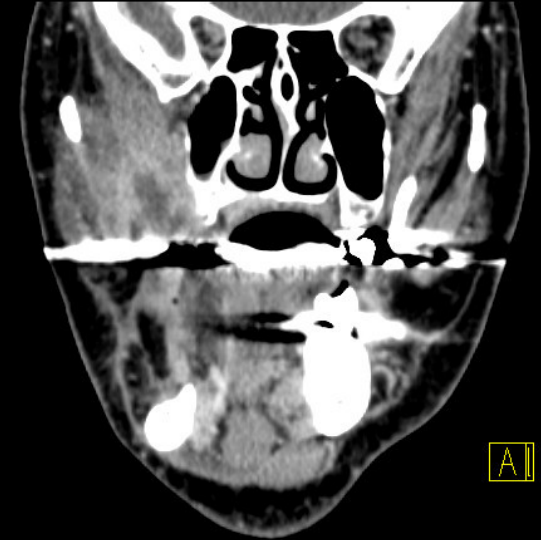
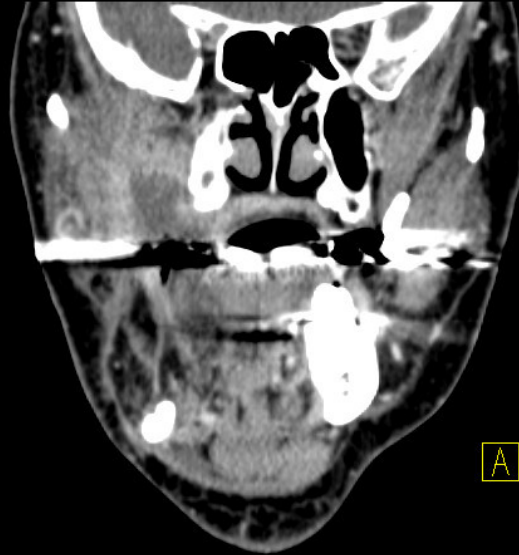
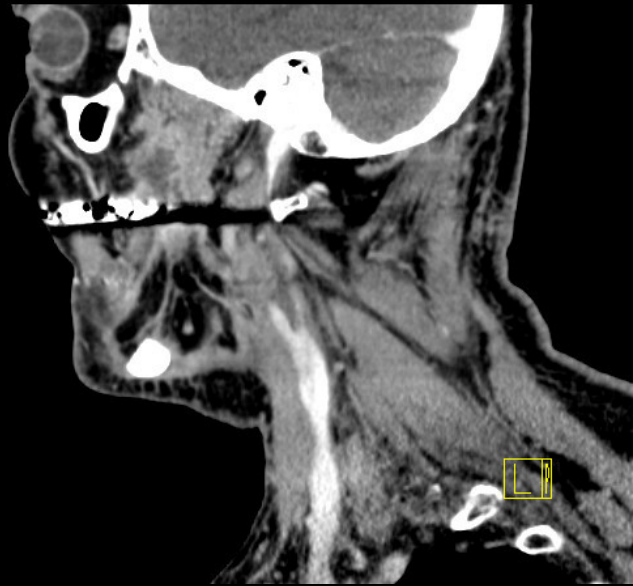
Patient 2 – Bilan d'extension d'une tumeur ethmoïdale



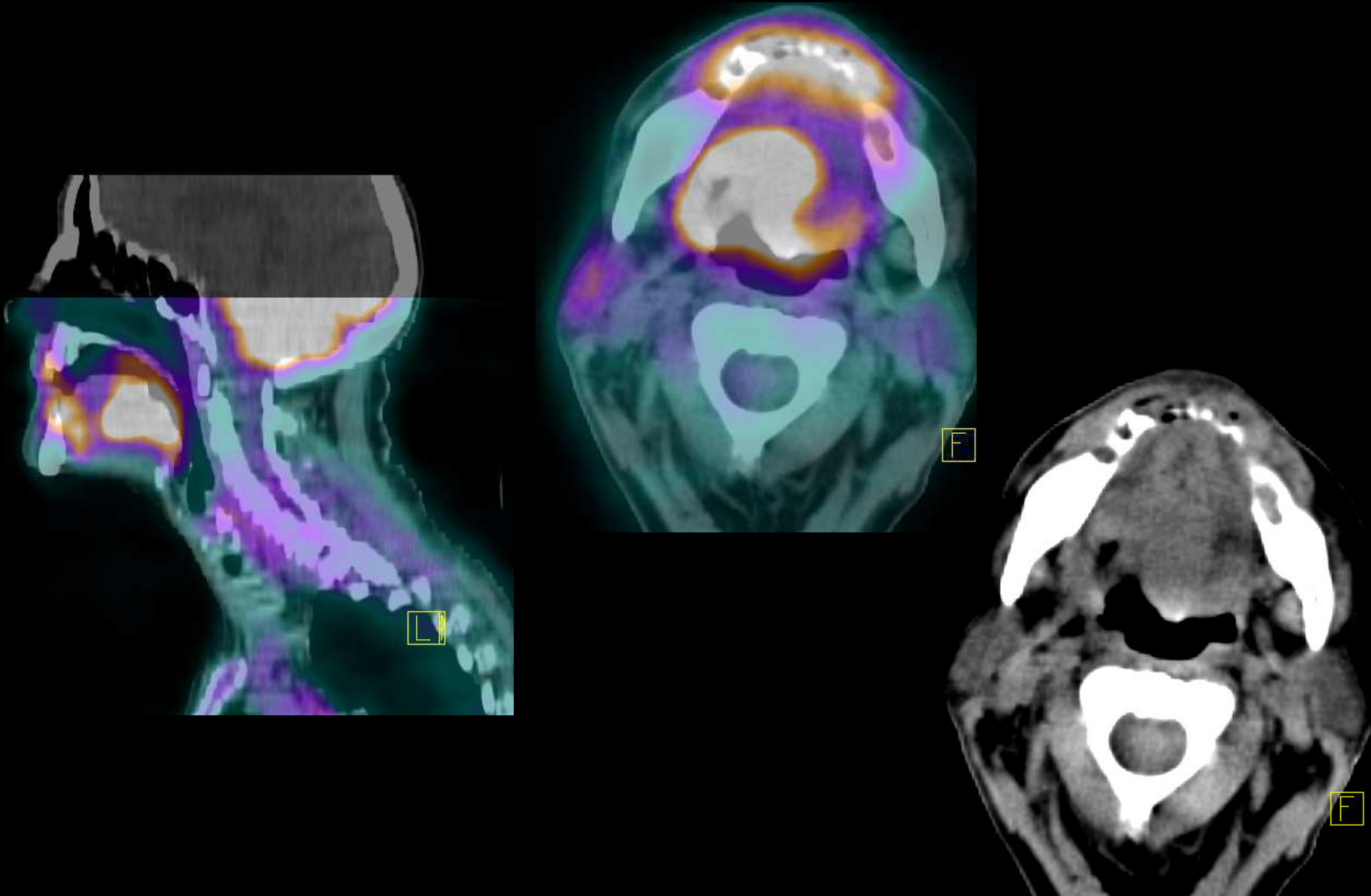
Patient 3 – Récidive d'une tumeur du trigone rétromolaire



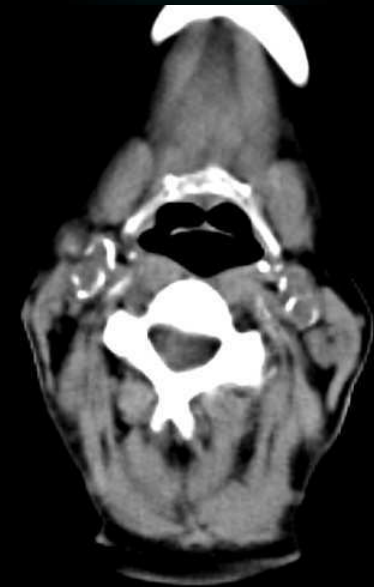
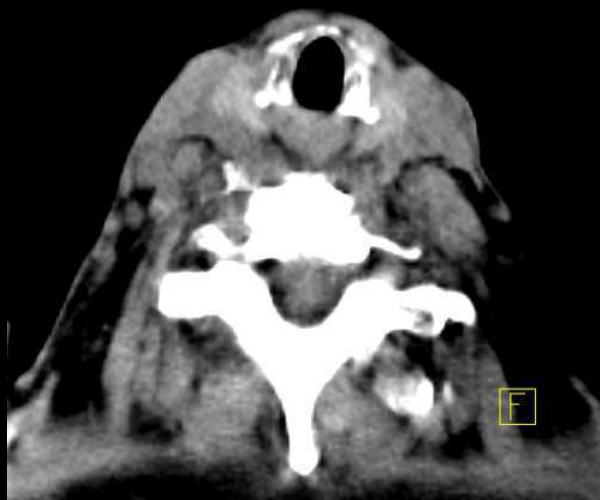
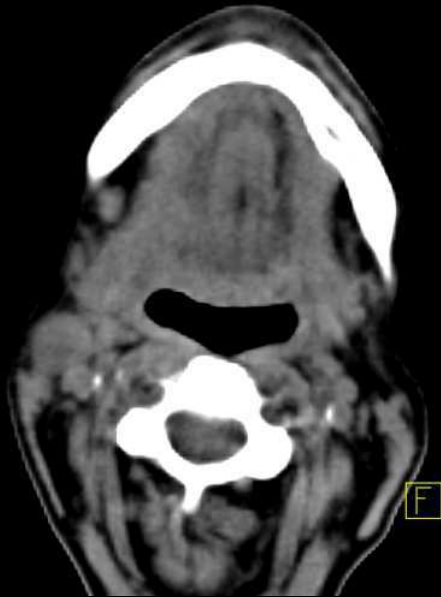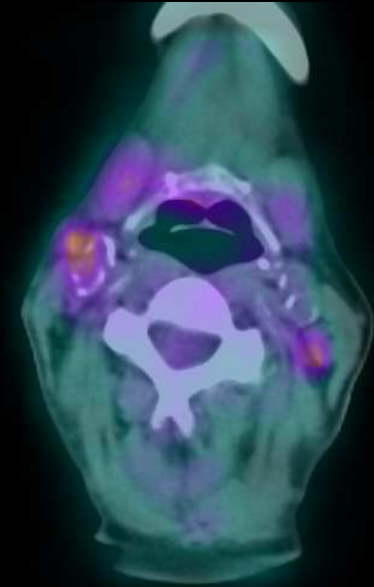
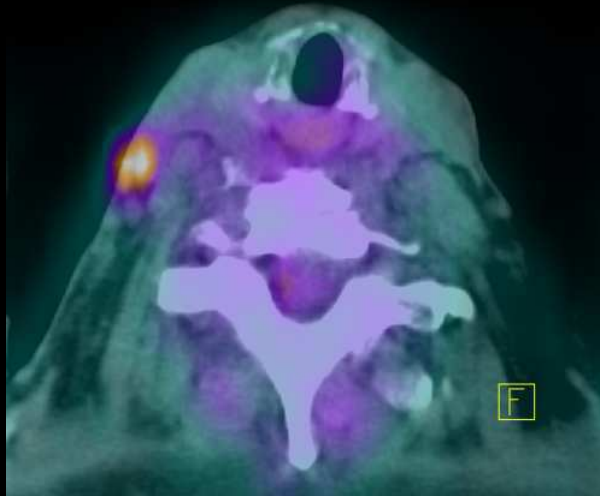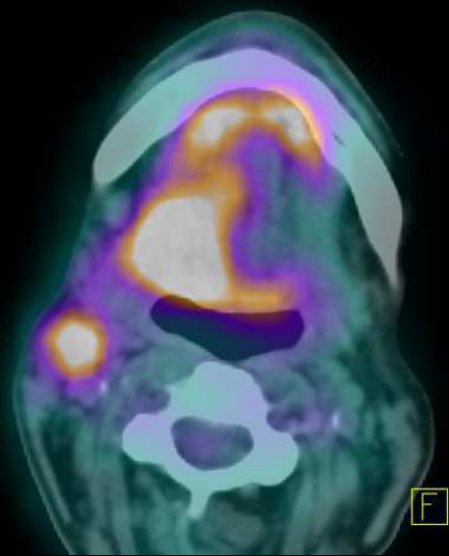
Patient 3 – Récidive d' une tumeur du trigone rétromolaire



Patient 4 – Carcinome de langue



Patient 4 – Carcinome de langue



Patient 5 – « Tumeur » parotidienne D

