

## Cyst Formation in Gastric Heterotopic Pancreas: Report of Two Cases<sup>1</sup>

Cyst formation is an uncommon pathologic finding in heterotopic pancreas. It is sometimes reported in a duodenal location but very rarely in a gastric location and leads to very large lesions of unusual endoscopic and radiographic appearance. Two cases of gastric heterotopic pancreas are described in which cystic zones in the gastric wall were found at preoperative ultrasound or computed tomography.

**Index terms:** Pancreas, ectopic, 72.314 • Stomach, CT, 72.1211 • Stomach, cysts, 72.312 • Stomach, US studies, 72.1298

Radiology 1988; 169:659-660

**W**E report two cases of gastric heterotopic pancreas, the diagnosis of which was missed before and during surgery because of the large size and the atypical appearance of the lesions. Pathologic examination revealed a diffuse cystic formation that was visible on the preoperative ultrasound (US) or computed tomographic (CT) scans. Heterotopic pancreas with cyst formation is known to occur sometimes in the duodenum (1-4) but very rarely in the stomach (5,6). To our knowledge, the radiologic patterns of cyst formation in the stomach related to a heterotopic pancreas have not previously been described.

### CASE REPORTS

**Case 1.**—A 38-year-old man was admitted with a complaint of epigastric pain of several months duration. At endoscopy a large submucosal mass was discovered on the posterior wall of the antrum. The mucosa was not ulcerated, and no abnormality was seen in specimens obtained at superficial biopsy. The mass was sharp edged at double-contrast barium examination, suggesting a benign mesenchy-

mal tissue tumor (Fig 1a); on CT scans it was hypoattenuating and heterogeneous (Fig 1b). Surgery revealed a soft tumor of the antrum, which was enucleated after mucosal incision. Sectioning showed the mass to be hollow with cystic cavities. At microscopic examination, the gastric musculature was dissociated by heterotopic pancreatic structures, the largest of which contained islets of Langerhans and pancreatic ducts. These ducts gave rise to dilated cysts; both were bordered by pancreatic excretory or mucinous epithelium and surrounded by a dense fibrosis with very little inflammatory reaction (Fig 1c). Reexamination of the CT scan showed two areas of differing attenuation within the lesion: one central portion, homogeneously hypoattenuating (4-10 HU) and likely corresponding to the multicystic formation, and a peripheral hyperattenuating portion, probably representing the pancreatic heterotopic tissue (Fig 1b).

**Case 2.**—A 44-year-old man complained of epigastric pain of several years duration. Endoscopy showed an ulcerated lesion of the lesser antral curvature with an appearance of gastritis at biopsies. Examination after medical treatment no longer revealed the ulceration but showed a thickening of the stomach wall, which suggested a submucosal process. This finding was confirmed with a double-contrast upper gastrointestinal series (Fig 2a). US examination showed the stomach wall to be thickened and heterogeneous, with several fluid-filled zones 2-3 cm in diameter (Fig 2b). Surgery revealed an intensive infiltration of the lesser curvature and the antrum, associated with marked adenopathy. Because a neoplasm or lymphoma was suspected, a total gastrectomy with curettage of the lymph nodes was performed. Pathologic examination showed a thickened stomach wall containing 0.5-3.0-cm-diameter cysts, the largest of which appeared to correspond to the fluid-filled areas seen at sonography. Microscopic examination revealed a heterotopic pancreatic tissue with cystic changes; the lining of the cysts showed abrasions as a result of an intense inflammatory process (Fig 2c). There was no communication between ducts and the gastric lumen. The lymph nodes showed inflammatory changes.

### DISCUSSION

Clinical findings and findings at barium enema examination in case 1 suggested a benign mesenchymal tumor. In case 2, however, the substantial in-

flammatory reaction was a probable explanation for the pseudolymphomatous appearance. In both cases the common sign found retrospectively on US or CT scans was the presence of one or several fluid-filled zones, surrounded by a peripheral, solid, noncalcified portion of variable thickness.

Pathologic examination showed these fluid-filled zones to be related to the presence of cysts mingled with the pancreatic tissue. Their great number and their diameter, which could reach several centimeters, explains the large size of the lesion (the lesions are usually small; mean, <2 cm) (7). The existence of multiple cysts within a heterotopic pancreas is rare: Although several authors have reported cystic changes in duodenal ectopic pancreas (1-4), only two authors (5,6) have, to our knowledge, mentioned such a finding in gastric ectopic pancreas, and these reports included no radiologic assessment. The cysts are of ductal origin; the dystrophic origin proposed for the duodenal localization (4) appears to be most probable, since there exists no argument in favor of a mechanical or tumor origin. The presence of inflammatory manifestations seems to be a secondary complication occurring in the course of the disorder, since it was considerable in our case 2 but practically absent in case 1.

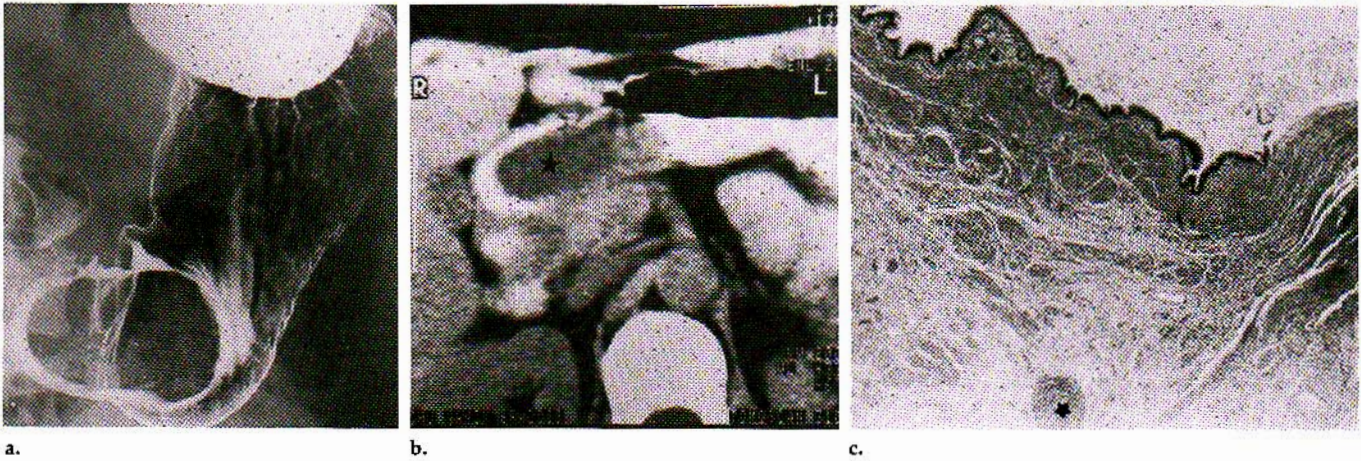
The radiologic patterns are not specific, so the differential diagnosis should also include other cystic masses that may be attached to the gastric wall, including especially necrosis in a tumor (8) or hematoma (9), but also including pancreatic pseudocysts, abscess, or mesenteric cysts, whose clinical presentations are different. Enteric duplication, however, is usually purely liquid (10) except if carcinoma arises within it (11). Similar radiologic patterns have also been described for some other congenital gastric cystic lesions such as choristoma with respiratory epithelial differentiation on histologic examination (12,13). On the other hand, pancreatitis or abscess may sometimes occur in gastric heterotopic pancreas (14,15).

In conclusion, in the setting of a large gastric submucosal mass with demonstration of internal fluid-filled zones on US or CT scans, a cystic formation in heterotopic pancreas should

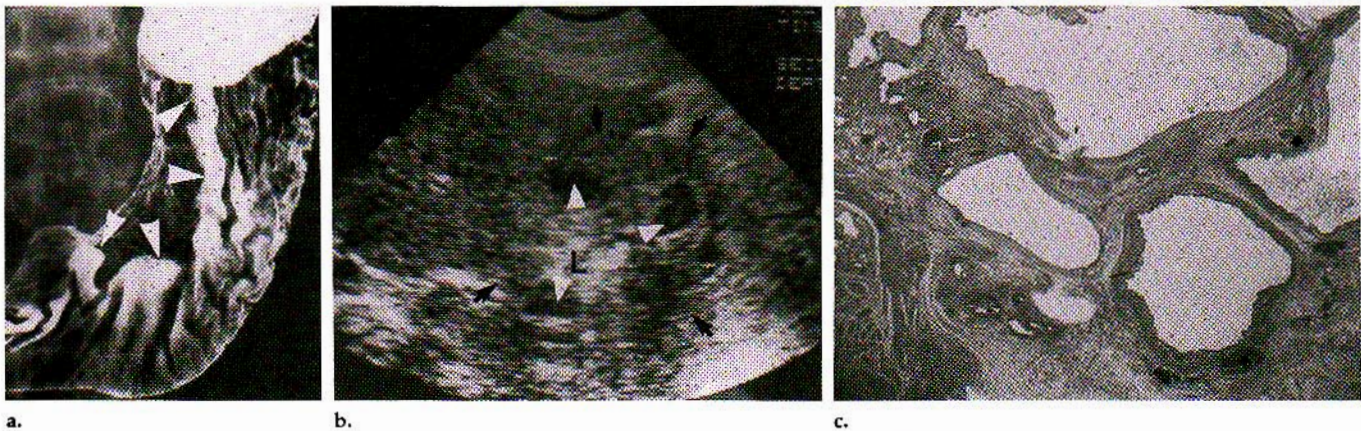
<sup>1</sup> From the Departments of Radiology (M.C., D.R.), Pathology (A.L.V., J.F.), Hepatogastroenterology (M.A.B.), and Surgery (P.B., P.P.), Centre Hospitalier Régional et Universitaire de Nancy, Hôpital de Brabois, RN 74, 54500 Vandœuvre les Nancy, France. Received April 4, 1988; revision requested May 12; revision received June 27; accepted July 15. Address reprint requests to M.C.

© RSNA, 1988





**Figure 1. Case 1.** (a) Double-contrast barium study shows large, sharp-edged submucosal mass in the antrum. (b) CT scan through the mass demonstrates a central area of low attenuation (4-10 HU) (★) corresponding to the cystic area. (c) Microscopic view of pathologic section from the peripheral muscular layer shows cyst bordered by an excretory epithelium fibrosis and several pancreatic lobules (★) (hematoxylin and eosin staining; original magnification,  $\times 40$ ).



**Figure 2. Case 2.** (a) Double-contrast barium study shows a large mass (arrowheads) infiltrating the lesser curvature and the adjacent wall of the stomach. (b) US image demonstrates the presence of liquid zones (arrowheads) through the thickened wall (arrows). L = lumen. (c) On microscopic section the presence of cysts and several pancreatic lobules (★) in the submucosal layer is documented (hematoxylin and eosin staining; original magnification,  $\times 5$ ).

be considered as part of the differential diagnosis, especially if the lesion is in the antrum or in the gastric curvatures (16,17). The diagnosis should be verified by means of a surgical-pathologic examination, the results of which allow limited excision. Surgical-pathologic examination is especially necessary if inflammatory phenomena mimic a neoplastic process, as in our second case. ■

#### References

- Eloit S, Charles JF, L'Heveder G, Balouet G, Leroy JP. Dystrophie kystique sur pancréas aberrant. *Arch Anat Cytol Pathol* 1987; 35:17-21.
- Leger L, Lemaigre G, Lenriot JP. Kystes sur hétérotopies pancréatiques de la paroi duodénale. *Nouv Presse Med* 1974; 3:2309-2314.
- Murat J, Gignoux M, Lesbros F. Dystrophie kystique sur pancréas aberrant du bulbe duodénal: un cas avec symptomatologie clinique. *Ann Chir* 1971; 25:1203-1208.
- Potet F, Duclert N. Dystrophie kystique sur pancréas aberrant de la paroi duodénale. *Arch Fr Mal App Dig* 1970; 59:223-238.
- Martinez NS, Morlock CG, Dockerty MB, Waugh JM, Weber HM. Heterotopic pancreatic tissue involving the stomach. *Ann Surg* 1958; 147:1-12.
- Nicolesco S, Velciu V. Contribution à l'étude morphologique des hétérotopies pancréatiques du tube digestif. *Arch Anat Pathol* 1968; 16:271-280.
- Barrocas A, Fontenelle LJ, Williams MJ. Gastric heterotopic pancreas: a case report and review of literature. *Ann Am Surg* 1973; 175:361-365.
- Kaftori JK, Aharon H, Kleinhaus U. Sonographic features of gastrointestinal leiomyosarcoma. *JCU* 1981; 9:11-15.
- Gordon RA, D'Avignon HB, Storch AE, Eyster HE. Intramural gastric hematoma in a hemophilic with an inhibitor. *Pediatrics* 1981; 67:417-419.
- Thornhill BA, Cho KC, Morehouse HT. Gastric duplication associated with pulmonary sequestration: CT manifestations. *AJR* 1982; 138:1168-1171.
- Mayo HW, McKee EE, Anderson RM. Carcinoma arising in reduplication of the stomach (gastrogenous cyst): a case report. *Ann Surg* 1955; 141:550-555.
- Gensler S, Seidenberg B, Rifkin H. Ciliated lined intramural cyst of the stomach. *Ann Surg* 1966; 163:954-956.
- Tanenbaum B, Levowitz BS, Ponce M, Manubay S. Respiratory choristoma of stomach. *NY State J Med* 1971; 71:373-375.
- Green PH, Barratt PJ, Percy JP, Cumberland VH, Middleton WR. Acute pancreatitis occurring in gastric aberrant pancreatic tissue. *Dig Dis Sci* 1977; 22:734-740.
- Grosdidier J, Coxam B. Abcès de la paroi de l'estomac: complication d'un îlot pancréatique aberrant. *Presse Med* 1957; 65:983-984.
- Palmer ED. Benign intramural tumors of the stomach: aberrant pancreatic tumors. *Medicine* 1951; 30:83-91.
- Pearson S. Aberrant pancreas: review of the literature and report of three cases. *Arch Surg* 1951; 63:168-184.